

MEETING ABSTRACT

Open Access

Palliative treatment of bone metastases: analysis of biological effects of MR guided Focused Ultrasound (MRgFUS) versus External Beam Radiation Therapy (EBRT). A randomized comparative trial using Functional Diffusion Maps as molecular activity indicator

Michele Anzidei*, Alessandro Napoli, Giulia Brachetti, Maurizio Del Monte, Daniel De Olivera, Fabrizio Andrani, Carola Palla, Luca Bertaccini, Daniela Musio, Vincenzo Tombolini, Carlo Catalano

From 2nd European Symposium on Focused Ultrasound Therapy
Rome, Italy. 10-11 October 2013

Background

New functional and metabolic imaging techniques may provide the ability to assess biological changes that act as indicators of therapy response [1,2]. Particularly, Diffusion-Weighted Imaging (DWI) can be used to monitor change in cellularity within the tumour over time, which is reflective of response to therapy [3-5]. Our study aims to investigate and compare the response to MR guided Focused Ultrasound (MRgFUS) and External Beam Radiation Therapy (EBRT) treatments of painful bone metastases by using DW Magnetic Resonance imaging (DW-MRI) with apparent diffusion coefficient (ADC). Furthermore, we analyzed the correlation between DW-MRI and the Visual Analogue Scale (VAS).

Materials and methods

This prospective, double arm, randomized study with EBRT serving as control arm, received IRB approval. 36 consecutive patients (female:15 male:21 mean age:60.3) with painful bone metastases were enrolled. 18 patients underwent MRgFUS treatment, using ExAblate 2100 system (InSightec), and 18 patients underwent EBRT. Pain palliation was evaluated by visual analog scale (VAS), pain questionnaires and changes in the patients'

medication. All patients underwent 3T ce-MRI (Discovery 750, GE; gd-BOPTA, Bracco) before treatment and at 1, 2, and 3 months afterward. MRI protocol included DWI sequences with five *b* factors (0–800 s/mm²) and ADC were obtained. The average ADC values for each lesion were analyzed in comparison between pre- and post-treatment.

Results

No treatment-related adverse events were recorded for both arms. Statistically significant difference between baseline and follow-up VAS values and medication intake for both MRgFUS and EBRT patients ($p < 0.05$) was noted. DWI showed substantial increase in mean ADC values after treatment for both MRgFUS (pre:1080,6±269 mm²/s; post: 1577,5±311,6) and EBRT (pre:1313,3±424,3 mm²/s; post:1777,9±386,3); there were no significant statistical differences in ADC shift following between MRgFUS and EBRT ($p > 0.5$). Progressive decrease in VAS values positively correlated to an increase in mean ADC values ($p > 0.01$) for both treatment modalities (Tables 1, 2).

Conclusions

DW-MRI with ADC is a viable option for assessing tumor response to MRgFUS therapy for bone metastases. The increase in mean ADC values of ablated bone

* Correspondence: michele.anzidei@gmail.com

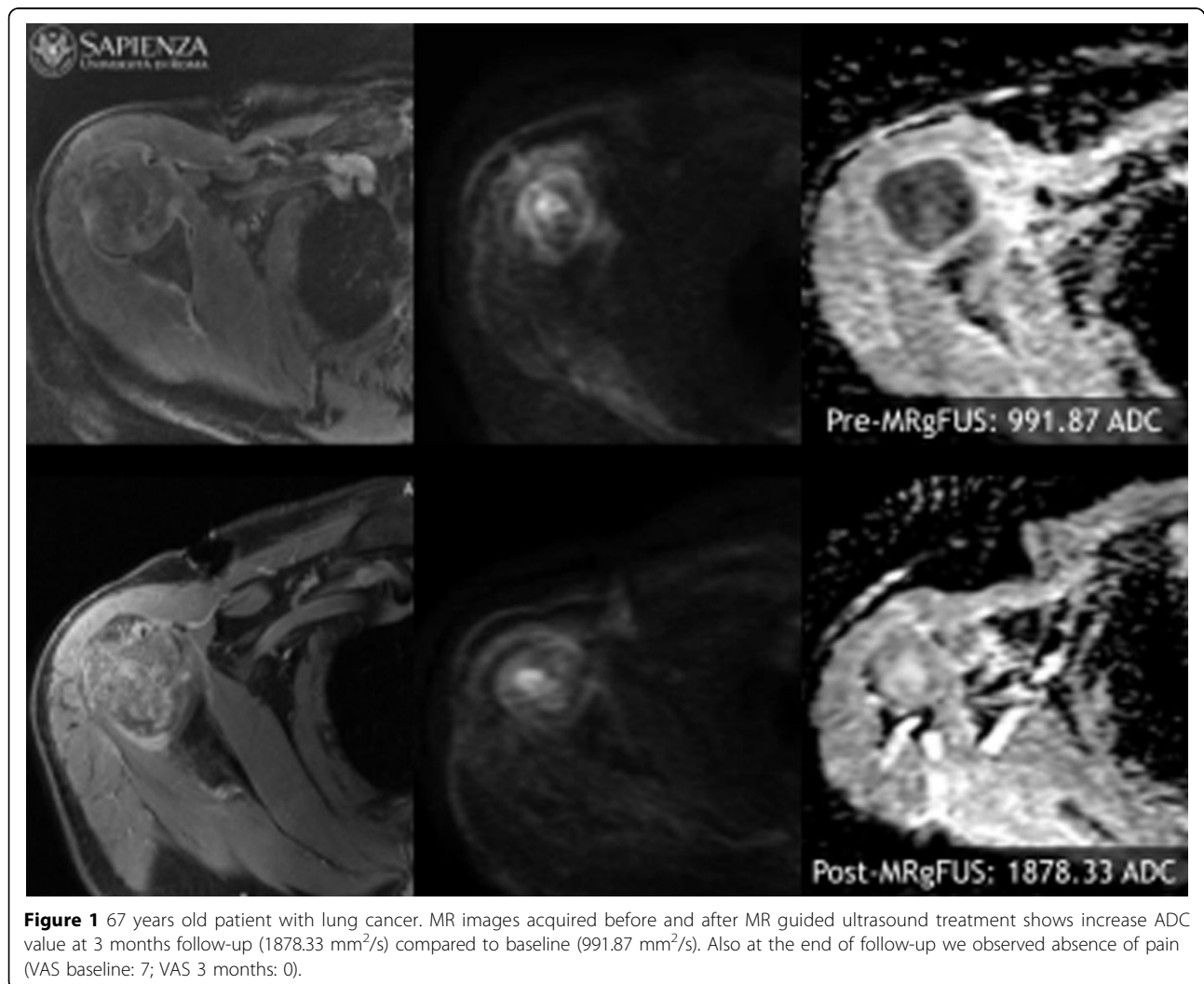
Department of Radiological Oncological and Pathological Sciences,
"Sapienza" University of Rome, Italy

Table 1

| MRgFUS | baseline | Follow-up 1 month | Follow-up 2 months | Follow-up 3 months |
|--------|-------------------------------|-------------------------------|---------------------------------|---------------------------------|
| ADC | 1080.6±269 mm ² /s | 1347.2±294 mm ² /s | 1428.7±306.7 mm ² /s | 1577.5±311.6 mm ² /s |
| VAS | 7.09±1.8 (range 4-10) | 2.65±1.36 (range 0-5) | 1.04±1.91 (range 0-6) | 1.09±1.99 (range 0-6) |

Table 2

| EBRT | baseline | Follow-up 1 month | Follow-up 2 months | Follow-up 3 months |
|------|--------------------------------|-------------------------------|-------------------------------|---------------------------------|
| ADC | 1313.3±424.3mm ² /s | 1463±361.7 mm ² /s | 1611±373.2 mm ² /s | 1777.9±386.3 mm ² /s |
| VAS | 6.12±1.1 (range 5-10) | 3.51±1.54 (range 0-6) | 1.32±1.48 (range 0-4) | 1.02±1.36 (range 0-4) |



metastases could reflect pathophysiologic alterations that occur after ablative therapy [6]. It is therefore possible that ADC variations could effectively describe and express effects on tumor mass control induced by

focused ultrasound ablation. MRgFUS is a promising noninvasive treatment modality for successful palliation of bone metastasis [7] and has potential for tumor control (Figures 1, 2) [8] as compared to ERBT. MRgFUS

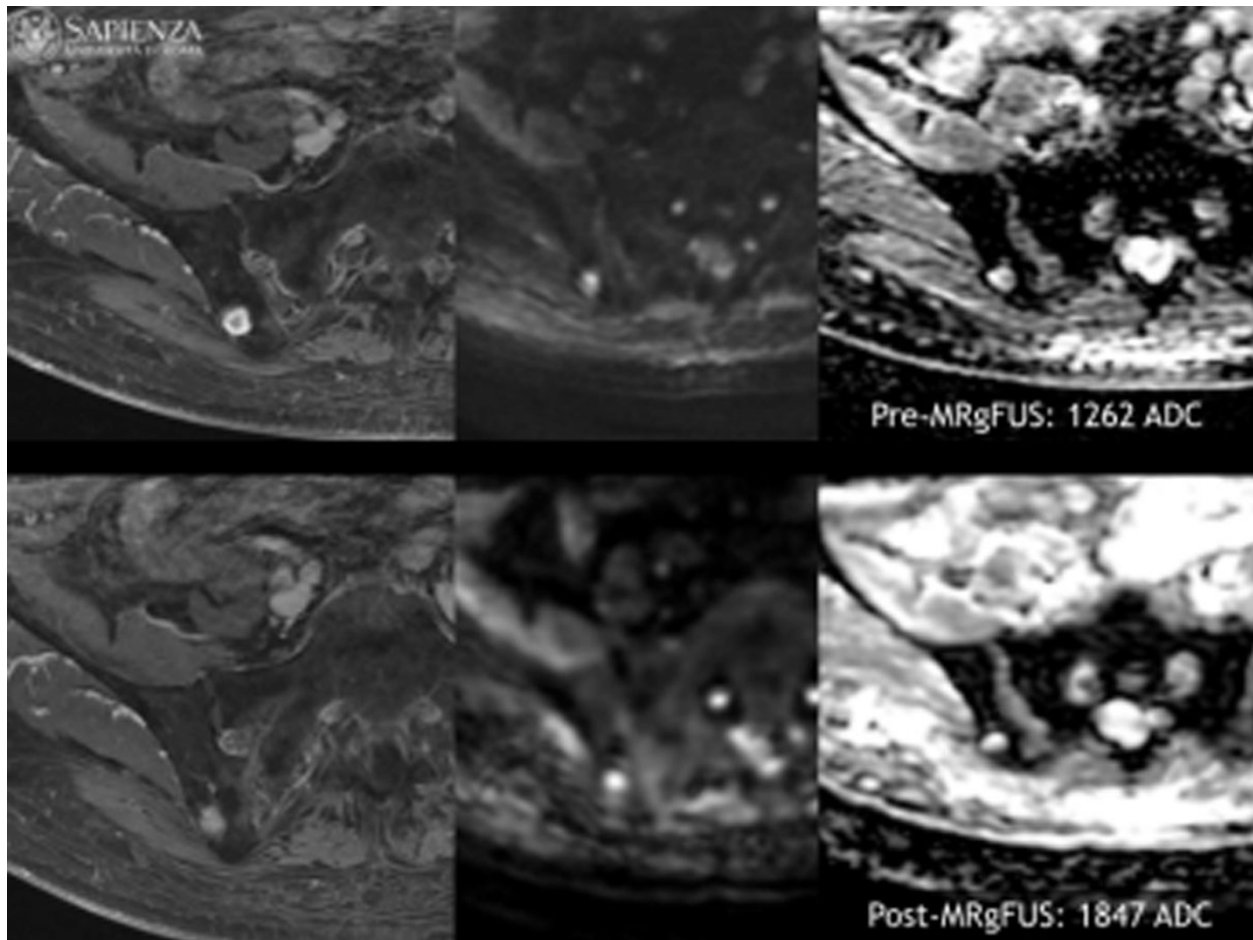


Figure 2 70 years old patient with renal cell carcinoma. Same as figure 1, it has been verified an increase ADC value after MR guided ultrasound treatment (ADC baseline: 1262 mm²/s. ADC 3 months: 1847 mm²/s). At 3 months follow-up VAS value 4 (VAS baseline 8).

determines bone metastasis cell damage similarly to EBRT as demonstrated by linear ADC modification.

Published: 10 December 2014

References

1. Harry VN, et al: Use of new imaging techniques to predict tumour response to therapy. *Lancet Oncol* 2010, **11**:92-102.
2. Vassiliou V, et al: Bone metastases: assessment of therapeutic response through radiological and nuclear medicine imaging modalities. *Clin Oncol (R Coll Radiol)* 2011, **23**(9):632-45.
3. Charles-Edwards EM, et al: Diffusion-weighted magnetic resonance imaging and its application to cancer. *Cancer Imaging* 2006, **6**:135-143.
4. Reischauer C, et al: Bone metastases from prostate cancer: assessing treatment response by using diffusion-weighted imaging and functional diffusion maps. Initial Observations. *Radiology* 2010, **257**:2.
5. Mardor Y, et al: Early detection of response to radiation therapy in patients with brain malignancies using conventional and high b-value diffusion-weighted magnetic resonance imaging. *J Clin Oncol* 2003, **21**(6):1094-100.
6. Smith NB, et al: Thermal effects of focused ultrasound energy on bone tissue. *Ultrasound Med Biol* 2001, **27**(10):1427-33.
7. Napoli A, Anzidei M, Marincola BC, Brachetti G, Noce V, Boni F, Bertaccini L, Passariello R, Catalano C: MR Imaging-guided Focused Ultrasound for

Treatment of Bone Metastasis. *Radiographics* 2013, **33**(6):1555-68, doi: 10.1148/rg.336125162.

8. Napoli A, Anzidei M, Marincola BC, Brachetti G, Ciolina F, Cartocci G, Marsecano C, Zaccagna F, Marchetti L, Cortesi E, Catalano C: Primary pain palliation and local tumor control in bone metastases treated with magnetic resonance-guided focused ultrasound. *Invest Radiol* 2013, **48**(6):351-8, doi: 10.1097/RLI.0b013e318285bbab.

doi:10.1186/2050-5736-2-S1-A17

Cite this article as: Anzidei et al: Palliative treatment of bone metastases: analysis of biological effects of MR guided Focused Ultrasound (MRgFUS) versus External Beam Radiation Therapy (EBRT). A randomized comparative trial using Functional Diffusion Maps as molecular activity indicator. *Journal of Therapeutic Ultrasound* 2014 **2**(Suppl 1):A17.